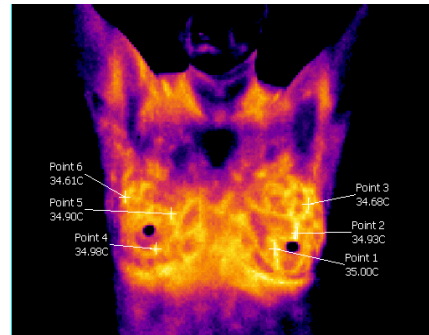
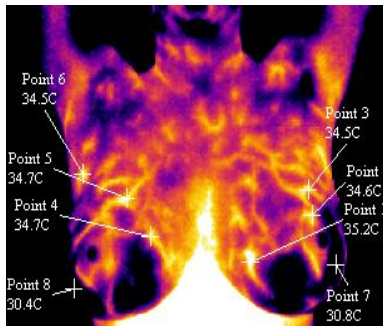


Thermo-Tech Inc.

Thermography During Lactation

Medical Thermography using a high-grade resolution infrared camera with a diagnostic computer program sensitive within 1/100th of a degree to enable accurate report generation, is the most accurate way to do a comparative gradient study of breasts. It doesn't put any radiation into the breast so it is safe for all women even those who are pregnant or lactating. It has been tested in a study at the Pasteur Institute in Marseilles France to have a 9% error rate for both false positive and false negative. This is far superior to Mammography which has an 80% false positive and a 40% false negative in post-menopausal women with soft breasts and a 60% false negative in pre-menopausal women with dense breasts. Thermography accuracy rate is not effected by breast density in any way. The Marseilles study followed a group of 3,000 women over a 5 year period and referred back to images to determine those with breast cancer in varying stages in order to design a rating on a scale of TH-1 which is benign to TH-5 which indicates a 96% risk of breast cancer.

In lactating women the estrogen levels increase as does the blood supply bilaterally(in both breasts) thus aiding in the supply of milk. Some post-menopausal women will look estrogen dominant in their thermography which will show up as excessive vascular-like features bilaterally due to the fact that during the post-menopausal period the progesterone, that is needed during pregnancy, decreases making the breast look estrogen dominant. See images below to note the excessive vascular like feature of a post-menopausal estrogen dominant woman and a lactating woman.

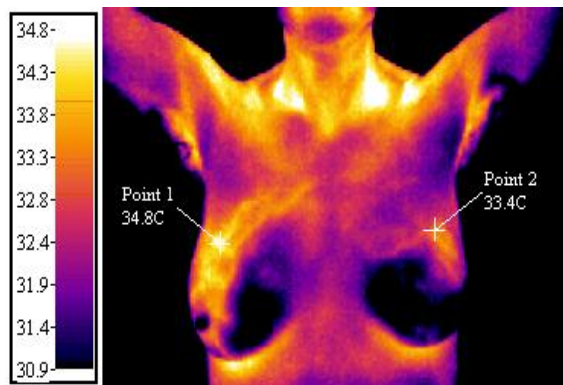


Estrogen Dominant Post-Menopausal Woman

Lactating Woman

One factor to consider in Thermal Imaging for a lactating woman is that Thermography uses comparative analysis to rate the breasts because breast cancer shows up asymmetric (one sided). Frequently lactating women have a dominant side that the baby favors or a breast that produces milk better than the other. This will cause an asymmetric pattern and giving the breast that has a more prominent patter an atypical rating most likely a TH-3. Note should be made that features that are suspicious of breasts cancer are very different than this slightly asymmetric pattern of a lactating female with a prominent side. See image below for what an asymmetric pattern of breast cancer will show up like.

Thermo-Tech Inc. Thermography During Lactation (Continued)



TH-5 Rating in Thermography using the Marseilles Classification with a 96% risk for malignance, shows an asymmetric vascular-like hyperthermic (hot) pattern in the two quadrants (cranial lateral and caudal lateral) of the right breast (at point 1). This is indicative of neo-angiogenesis (a blood supply that specifically develops to feed a cancerous tumor). In comparing this feature to the contra-lateral breast at point 2 you can see that it is also 1.4°C above base emission levels so both the vascular-like pattern covering two quadrants and emission levels are factors that put it in this TH-5 high rating category.

The most common problem for lactating women with a newly developing lump or breast tenderness is a clogged mammary duct, mammary duct infection or mastitis. Caster Oil pack applied to a clogged mammary duct saturated onto cotton flannel and covered with a hot water bottle or heating pad is an old Edgar Casey remedy that is quite effective when accompanied with massage. For more information about 'Healing a Mammary Duct Infection' read that article on the www.HealthyBreasts.info website under 'Handouts' in the top menu then go to 'Articles'.

Thermography is an excellent technique for screening all women of all ages and stages of life for breast cancer as it is far more accurate and there is no harmful carcinogenic radiation or painful compression to traumatize the breast.

About the Author:



Nancy Gardner-Heaven is board certified as a Technician of Medical Thermology at Auburn University. She presented her case studies reversing DCIS or Ductal Carcinoma in Situ in 80% of patients in this study, to the American Board of Thermology, at Auburn University in 2003. This study has been published in the Townsend Letter Magazine.

She has been teaching about preventing life threatening diseases at San Francisco State, UC Berkeley and the University of Hawaii in Hilo and offers these classes free to the public in various locations around the San Francisco Bay Area, California and Hawaii.

For more information about the locations of Thermography Screening, Free Classes or to schedule an appointment for thermography visit our website at:

[www. HealthyBreasts.info](http://www.HealthyBreasts.info) or call (209) 881-3044

Thermo-Tech Inc. www.HealthyBreasts.info P.O. Box 891 Knights Ferry CA 95361-2091 (209) 881-3044

All rights reserved internationally © January 9, 2015