

## Time for Women to have a Healthier Choice in Breast Screening

Are Mammograms failing us as a diagnostic tool? Many women are refusing to have an annual mammogram. The thought of smashing delicate breast tissue and exposing themselves to carcinogenic radiation (4) in order to see if their breasts are healthy, just doesn't seem sensible. This is especially true when considering the error rate of a 40% false negative in postmenopausal women, a 60% false negative rate in women with dense breast tissue and a 80% false positive rate. (1) Out of that 80% false positive, the result is that many women undergo unnecessary, invasive surgical procedures without being informed about far less damaging options. A biopsy of a pre-cancerous lump breaches the encapsulation, can spread it outside the duct, expose it to a blood supply which can turn it into invasive cancer. This is unnecessary when research has proven these pre-cancerous lumps or Ductal Carcinoma in Situ, in most cases, can be reversed with an immune supportive protocol. (3) When considering that post-mortem statistics show that 40% of the adult female population have DCIS or pre-cancerous cells in their breasts, and one out of every eight women will be diagnosed with cancer in her lifetime these invasive procedures are actually increasing the rate of breast cancer.

Between 1973 and 1981 an in-depth study was conducted by the American Cancer Society and National Cancer Institute called the *Breast Cancer Detections and Demonstration Projects* or BCDDP. It concluded that: both mammogram and thermogram techniques were lacking in their own way but they chose mammography simply because it could localize a lesion. (4)

Thermography, however, sees the development of neo-angiogenesis, a blood supply that feeds a cancerous tumor, at a very early stage. Research shows Targeted Ultrasound which is painless and emits no carcinogenetic radiation, has a 99.9% accuracy rate in distinguishing if a lump is fluid-filled (as seen with infections i.e. acute cysts) or solid-filled with shadow margins (as seen with malignancy). Furthermore this study says: "The added value of adjunct with mammography is low", (5) meaning is not necessary.

In 1996, the Head of Radiology at University of California at Berkeley, John Goffman MD., PhD., after five years of research, published his findings on how many RADS of radiation it takes to cause [breast] cancer. He thought this information so important, that he published the findings on the cover of his book, *Preventing Breast Cancer*. "Our estimate is that about three-quarters of the current annual incidence of breast-cancer in the United States is being caused by earlier ionizing radiation primarily from medical sources". (6) Goffman's meticulous research suggests that Mammography is actually causing the disease it is supposed to detect.

We must ask ourselves why we are radiating the population for screening just to find a lump when Thermography is a safe, non-assaultive, and non-invasive and more precise diagnostic tool: especially when coupled with Targeted Ultrasound, if indicated?

Note: Only with a sophisticated a Medical Grade Infrared Camera and Diagnostic Program can accurate reports be generated by a Certified Medical Thermologist. This is the way to offer

Thermography as a proven, accurate, and much less invasive breast screening and monitoring regimen.

## **How Accurate is Thermography and Can it Be Trusted as a Breast Screening Tool?**

Thermography is not just a way to find disease, but it is a tool to monitor breast health, without breast compression or radiation. Using the strict procedures outlined in the Marseilles Classification Study, the accuracy rate for both false positive and false negative for *Standardized Medical Thermography*© is 9%. (2) This accuracy rate came from a study in 1976, at the Pasteur Institute, in Marseilles France. In this study, top medical doctors in their respective fields, followed 3,000 women for five years using the results of the thermography readings: and additionally to histology reports to classify the different ratings of: TH-1 through TH-5 with related risk factors for malignancy. It should be noted that only a biopsy with a histology report can give a 100% positive diagnosis of malignant cells. Unlike Mammography, research has shown that with a Comprehensive Immune Support Protocol© using Thermography as a monitoring tool, 80% of women with Atypical ratings reverse within three to six months. (3) Using this method has saved hundreds of women from unnecessary invasive procedures.

## **How to Choose a Thermography Clinic that Follows These Procedures**

Here are the factors to establish if a clinic is following Comprehensive Breast Screening© with Standardized Medical Thermography© criteria:

1. Does the clinic take a comprehensive reproductive history in addition to the details about any critical health issue?
2. Is the technician qualified to conduct a manual breast exam and recognize palpation of a suspicious lump, dimpling, or inverted nipple: Paggett's Disease (breast cancer of the nipple) or inflammatory breast cancer (that doesn't have a lump)? The technician should note the details about their findings on patient intake forms so changes can be monitored.
3. Does the clinic take images before and after performing the autonomic challenge as outlined in the Marseilles Procedures? This is important to distinguish neo-angiogenic blood vessels (that set up to feed a tumor), from normal blood vessels. The autonomic challenge is acquired by placing the patient's hands on ice for one minute. A full set of images, frontal and side views at 45 and 90 degrees on both sides, are taken before and after the autonomic challenge. Results of the comparison are then noted in the report.
4. Does the clinic provide the patient with a comprehensive report that notes the difference in specific features on the thermal images that need to be monitored when compared to those of the 'normal' breast? This is essential for monitoring improvements in these

features. [See the images below for an example of an abnormal reading that has improved with the necessary details noted on the images for comparison.]

5. Does the clinic include a comprehensive consultation with each report, to explain the content to the patient? It is important to go over the report in detail with the patient to answer questions, address concerns about specific features, symptoms or complaints, or the patient's health in general. By also including stress factors, the clinic be able to provide a Comprehensive Individualize Immune Support Protocol© to improve the patient's health. The clinic could recommend nutritional supplements to build the immune system or to address hormone imbalances; or could encourage making lifestyle changes to aid in a better sleep or to cope with stress.
6. With follow-up thermography sessions and reports, do the findings provide a visual comparison with the previous report so the patient can see if the specific feature of concern has improved or not?
7. Last but certainly not least, if the patient needs investigative and/or surgical procedures, professional staff should offer support so patients feel comfortable and safe and can make informed decisions rather than fear based ones. As professionals, they can only give accurate statistical information and never medical advice like a physician can.

### **Investigative and Surgical Procedures**

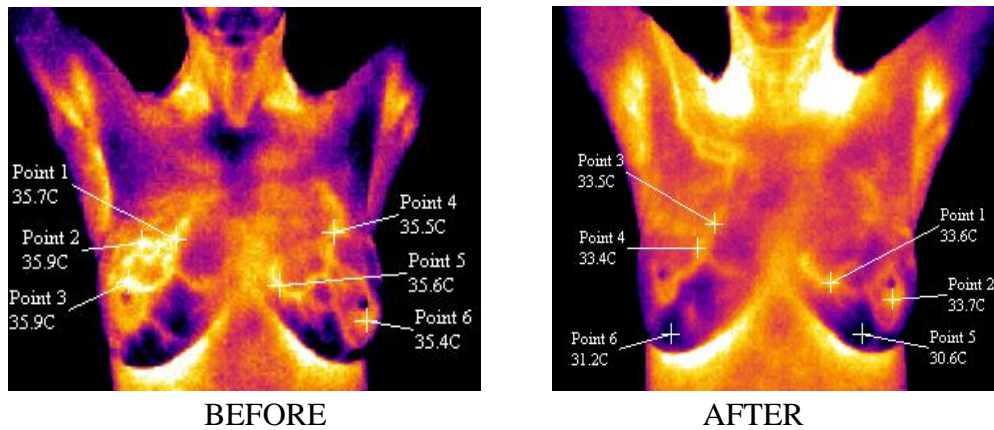
Early diagnosis of breast cancer before a malignancy has spread to the lymphatic system or other organs has a very good prognosis. However, performing a biopsy for a pre-cancerous condition like DCIS can in fact cause it to advance into an invasive malignancy. Although the Immune Support Protocol has proven to reverse Atypical Breast Thermography or DCIS in 80% of the cases, progress can be monitored with Thermography (see example below): 20% of cases do not improve. Some of those are Personal Variants, which means they simply have an asymmetric pattern that has not changed in years and is not progressing or worsening. For the others in which the features are progressively becoming more complex, more prominent, spreading to other quadrants, or having other features such as a growing lump or, dimpling of the breast or nipple, then other objective means of evaluation are recommended for these patients.

Targeted Ultrasound can isolate a lump and tell if it is fluid-filled (indicating an infection) or solid-filled. Solid-filled could be scar tissue or malignancy, the difference being with scar tissue that the margins would be clean compared to surrounding tissue as opposed to malignancy where the margins are shadowed an indication of it merging into surrounding tissue. If found early, a simple lumpectomy is usually sufficient. A sentinel node biopsy is performed during the surgery before the lump is removed by placing dye into the tumor. Dye leaks into connected lymph nodes which are then removed and a histology report about the lumps and sentinel nodes is generated. If there is no lymph involvement, then chemotherapy is contra-indicated.

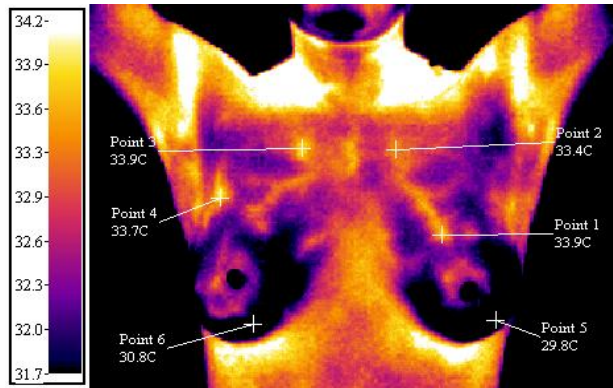
In this case doctors may suggest or even insist on radiation due to the surgical procedure or biopsy having liberated malignant cells. A patient has the right to be informed about the damage to lungs and heart (if the left breast is involved) through the use of radiation treatment. These stray malignant cells, if in fact there are any, can be addressed by using Turkey Tail Mushrooms to build the immune system. The patient will also be tested for an Estrogen or Progesterone receptor negative or positive. The oncologist may recommend some form of Tamoxifin which is normally prescribed for an Estrogen and/or Progesterone positive condition as a hormone blocker. A patient also has the right to know that this medication can cause uterine cancer. Other options for lowering the estrogen or progesterone is with Calcium D' Glucarate, which increases Phase 2 liver function to clean out excessive hormones and has been used to replace drugs like Tamoxifin with no side effects. Before, during, and after surgical procedures, the use of the homeopathic remedy, Arnica Montana, for trauma and injury is very helpful in preparing for surgery and in the post surgery healing process.

### Example of Thermal Images

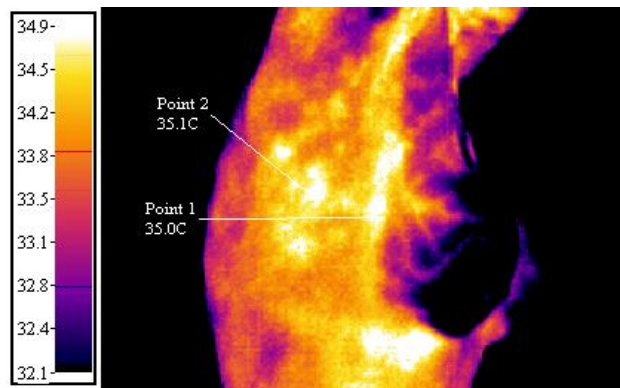
Below are images of a patient with Ductal Carcinoma in Situ (DCIS) before and after following an *Comprehensive Individualize Immune Support Protocol*®. (3) Pictured below are the proper notations of temperatures on the BEFORE image, comparing the atypical feature (Points 1-3) in the right breast with the left or 'normal' features in the left breast. In the AFTER image the atypical feature is gone.



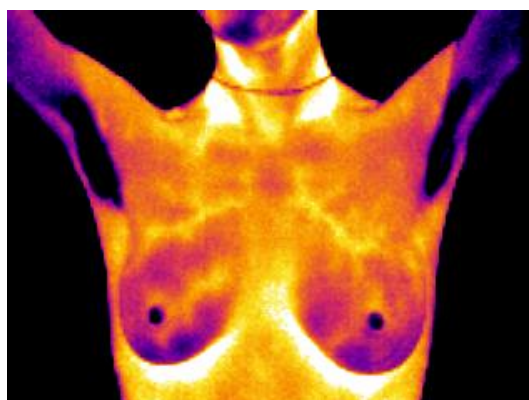
The image below is of a patient with a bilateral mammary duct infection, seen as diffuse hyperthermic patterns in the peri-areolar (nipple) region bilaterally. This atypical but benign condition can be addressed with the Healing a Mammary Duct Infection Protocol.



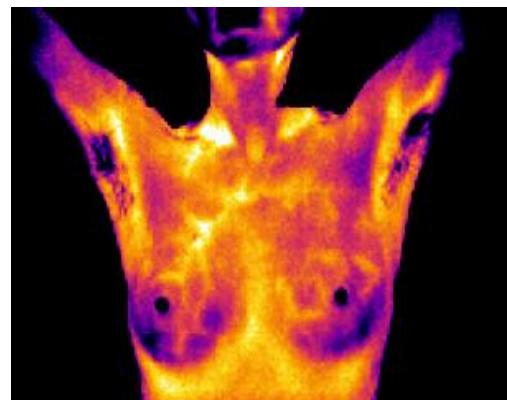
The image below is of a patient with 30-year-old augmentation implants that are decomposing and leaking into the lymphatic nodes and inflaming the liver. Thermography can help to reveal other reasons a patient is not feeling well. Not all health issues can be alleviated with nutritional protocols, but may need surgical procedures in addition, as in this case.



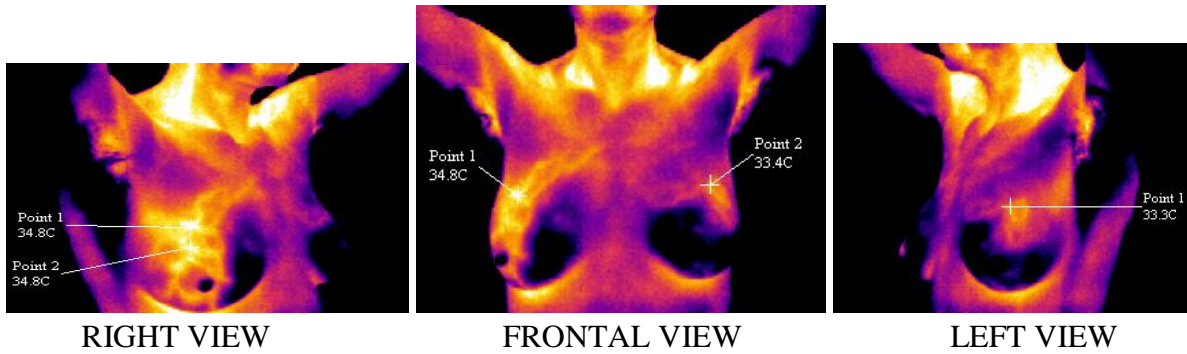
**Thermography Images Shows Benign, Atypical and Abnormal Ratings of Breasts**



Benign Thermography - TH-2  
with Symmetric Vascular-like Features.



Atypical Thermography - TH-3  
with one Asymmetric Vascular-like Feature.



Abnormal Thermography - TH-5 of the right breast with a complex vascular-like feature (Points 1&2 in the right view) indicating neo-angiogenesis, a blood supply associated with malignancy. A TH-5 rating has three criteria: 1. A complex vascular feature 2. This feature is seen in 2 quadrants, cranial lateral and caudal lateral and 3. It is 1.4°C above of base emission levels which is considered an anarch sign (a specific Thermography criterion). The left breast is rated: TH-2 or benign with no thermal features of concern, the hottest point noted for comparison.

### Conclusion

**Comprehensive Breast Screening® with Standardized Medical Thermography®, using Target Ultrasound for follow-up investigation when needed, is a far more accurate and less harmful technique for breast screening and monitoring women's breast health; and needs to be made available to all women.**

**It is time to stand up for our right to choose a more accurate and less harmful tool to screen and improve the health of our breasts.**

### Acknowledgements

The author would like acknowledge two prominent Bay Area Surgeons: Dr. Ann Verecoutere and Dr. William Small. Thank you for the kindness and respect you have shown my patients. Somehow thank you is not enough for the respect, knowledge, and willingness to answer numerous questions, that you have shown me. This service has been instrumental in giving me an indeph understanding of the scope of investigative tools, surgical procedures, and breast oncology in general. Also invaluable to me is my friendship with and the professional support of Dr. Lauren Eskinazi, author of *Reconstructing Aphroditie* and a phenominal Plastic Surgeon as well as artist in breast reconstruction.

### ABOUT THE AUTHOR



Article by Nancy Gardner-Heaven, Technician of Medical Thermology, Certified at Auburn University by the American Academy of Thermology. Nancy is a pioneer in the field of Medical Thermology offering *Comprehensive Breast Screenings®* using *Standardized Medical Thermography ©* for 25 years. Research from her immune boosting protocols

has proven to reverse DCIS and other Atypical Features in 80% of her patients. This study was presented at Auburn University at the American Academy of Thermology's Medical Conference<sup>(3)</sup> in 2003 and published in the Townsend Letter in 2004. Her published research has been instrumental in saving thousands of women from unnecessary surgical procedures. Nancy continues to improve this protocol as more substantial research surfaces. She is the founder of *Comprehensive Breast Screening*© with *Standardized Medical Thermography*© and has been using this technique since 1999. Comprehensive Breast and Full Body Screening is available in the greater San Francisco Bay Area as well as the Big Island and Kauai. See website: [www.HealthyBreasts.Info](http://www.HealthyBreasts.Info)

- (1) American Cancer Society Annual Statistics of Mammography Accuracy Rate.
- (2) Marseilles Classification Study at the Pasteur Institute in Marseilles, France 1976.
- (3) Abstract on Research of Immune Support Protocols Reversing Atypical Features presented at Auburn University, Published in the Townsend Letter.
- (4) Article: Infrared Imaging: Making Progress in Fulfilling Its Medical Promise Published in IEEE Engineering in Medicine and Biology Magazine by Drs Robert Elliott and Joanathan F Head Volume 21, Number 6 Nov/Dec 2002.
- (5) Article: Accuracy and Value of Breast Ultrasound for Primary Imaging Evaluation of Symptomatic Women 30-39 Years of Age Published in: American Journal of Roentgenology Diagnostic Imaging Related Sciences by November 2012, Volume 199, #5
- (6) Preventing Breast Cancer - The Story of a Major, Proven, Preventable Cause of This Disease by John W. Goffman, MD, Ph.D. Second Edition 1996 C.N.R. Book Division Published by: Committee for Nuclear Responsibility, Inc.
- (7) Abstract - Atypical Breast Thermology Case Study of Protocol Reversing DCIS and Other Atypical Breast in 80% of Patients, published in the Townsend Letter for Doctors and Patients- November 2004

**Contact Information:**  
**Nancy Gardner-Heaven**  
**P.O. Box 891**  
**Knights Ferry, CA 95361-2091**  
**Phone (209) 881-3044**

Intellectual Property by Nancy Gardner-Heaven All Rights Reserved Internationally © 2-2-19  
No portion of this article may be published without written consent and acknowledgement of the author